

# Neuro-cutaneous Syndrome (NCS): A New Disorder

© Copyright 2001 by Dr. Omar M. Amin, USA

## Abstract

A new neuro-cutaneous syndrome (NCS) is described. It is characterized by neurological sensation of movement subcutaneously and/or in deeper tissues and cavities that is usually associated with mucoid cutaneous lesions from

which one or more species of arthropods as well as unidentified fibers may be recovered.

## Introduction

This presentation is introductory in nature and is intended only to bring attention to a new disease entity that has not been previously reported. Attention is drawn herein to general manifestations of the initial pathology in a number of cases. No discussion of medical history, treatments, or outcome will be attempted at this time since most cases have not been satisfactorily resolved. These aspects will be discussed at a later date on a case by case basis as further progress allows and as more detailed information becomes available.

## Results and Discussion

The neurological aspects of NCS are characterized by movement sensations of what patients commonly describe as "parasites" subcutaneously and/or in various body tissues and sinuses particularly in the head. In the latter case, movement sensations is either unipolar or bipolar and may proceed horizontally (from one side of the head to the other) or vertically into the neck, chest, or abdomen as

well occasionally in the arms or legs. Movement sensations also occur subcutaneously in the head, body, or limbs that occasionally manifest as variably shaped bruises or waves of elevated ripples as personally observed by myself on the arm of JM (a patient).

The cutaneous aspects of NCS present in most cases experiencing the neurological aspects of the disorder. They usually present as open mucoid lesions that often grow and spread (*Figs. 1-3*), with fungal involvement. It is not known whether the fungal infections, when present, represent a causal factor in the lesion formation or secondary superimposed infection. Those patients are usually not immune compromised and have no intestinal parasites to which the cutaneous symptoms may have been a reaction. A common experience shared by most patients involve having puncture wounds, arthropod bites, or skin abrasions in a warm, moist, and moldy environment shortly before onset of symptoms.

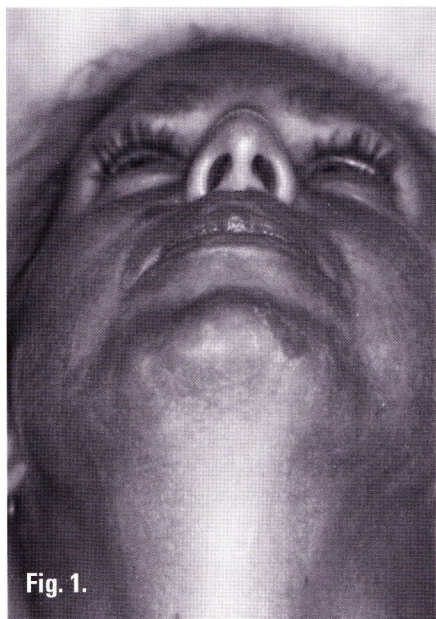


Fig. 1.

**Fig. 1.** Two receding lesions on the face of JM (1999), a young white American female from Colorado who spent time in Jamaica in the early 1990's where she had many insect bites and skin abrasions shortly before first appearance of symptoms.

**Fig. 2.** Lesions on the face of MM, a 40 year old white American female from California who had intimate exposure to a boyfriend and pets, among other exposures, with identical symptoms in 1995 just before onset of symptoms.

**Fig. 3.** Lesions on the leg of KC, a middle-aged white American female whose case information gathering is in progress.

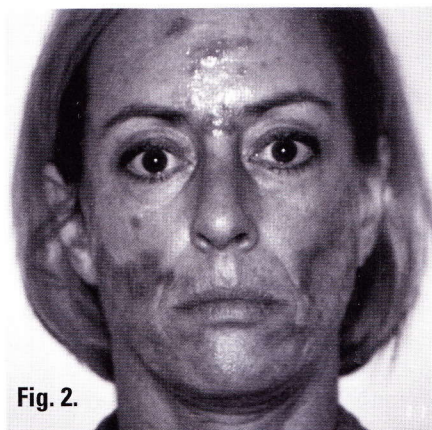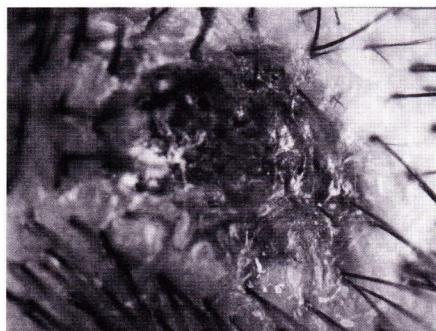


Fig. 2.

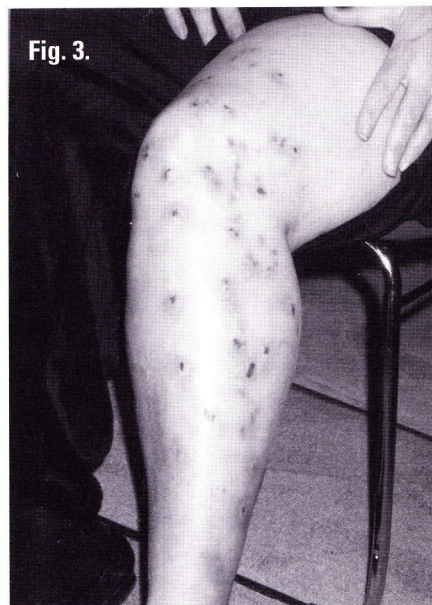

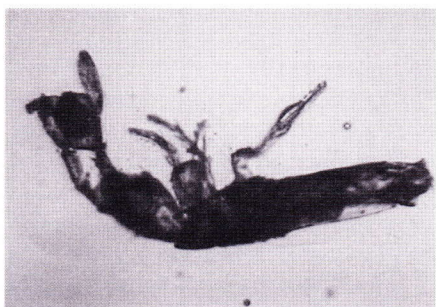Fig. 3.

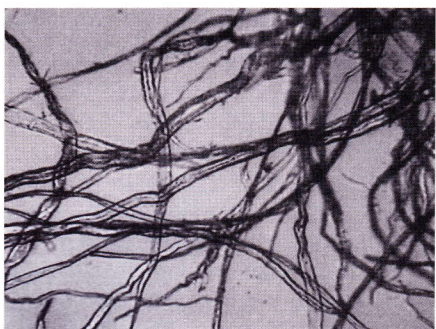



**Fig. 4.** One of a number of lesions on the scalp of JH.



**Fig. 5.** One of many springtails collected from scalp lesions of JH. The tail of that specimen was broken off; magnification 100X.



**Fig. 6.** Filaments from skin lesions of EL; magnification 1000X.

Skin lesions are sometimes associated with arthropod infestation which may represent secondary arthropod invasion attracted to already existing lesions that may be releasing fungal metabolites. Amin (1996) reported the recovery of a tick nymph, an oribated mite, and the following insects: ant, caterpillar, immature thrips, adult hymenopteran, crane fly parts, and other insect parts from facial lesions of SP (a patient) in 1994 and 1995. SP is a well nourished 185lbs, white American female born in 1936 who had a lengthy travel experience in Dubai, India, Malaysia, Bangkok, and Singapore. She moved into a moldy old home in an Oklahoma wooded rural area 3 miles from a toxic waste dump in April, 1991. She admitted to having had frequent facial contact with cats and tick bite(s) before onset of symptoms in August, 1991.

Scalp lesions also occur in patients with neurological symptoms and are usually associated with arthropod infestation. JH (a tall, healthy, well-nourished, middle aged white American female from Arizona) had a number of such lesions (Fig. 4) from which springtails (Collembola: Insecta: Arthropoda) (Fig. 5) were collected by myself in December, 1995. There is only two other published reports of springtails from humans (Hunter et al., 1960; Scott et al., 1962).

Unidentifiable filaments (non textile fibers) (Fig. 6) have also been associated with lesions in a number of patients. The nature and significance of this relationship is not clear at this time. Only Amin (1996) noted that the healing of SP's

lesions was "proportional to the exit of remaining fibers from lesions." EL (a young white unhealthy male from Florida) died from NCS which involved many such fibers (Fig. 6) and fungal spores from his skin lesions in 1995.

As briefly indicated in the introduction, information regarding medical history, additional symptoms, allopathic-herbal-light frequency generation treatment protocols, and resolution will be discussed in detail for each case separately in later publications. The National Pediculosis Association (NPA), Newton, Massachusetts retains a registry, and other relevant information, of most patients from the USA. I would like to invite any contributions that may help shed more light on this disorder. ♦

#### REFERENCES

- Amin, O. M. 1996. Facial cutaneous dermatitis associated with arthropod presence. *Explore* 7: 62-64.  
 Hunter, G. W., W. W. Frye, J. C. Schwartzwelder. 1960. *A Manual of Tropical Medicine*. W. B. Saunders, Philadelphia.  
 Scott, H. G., J. S. Wiseman, C. J. Stojanovich. 1962. *Collembola infesting man*, *Ann. Entomol. Soc. Am.* 55: 528-530.

#### ABOUT THE AUTHOR

Dr. Omar M. Amin is a regular contributor to *Explore*. He is a Professor of Parasitology and Founder of the Parasitology Center, Inc. 903 S. Rural Rd., #101-318, Tempe, Arizona, 85281 (formerly Diagnostic and Educational Laboratory, Institute of Parasitic Diseases, Phoenix, Arizona). He is a recognized authority in the field of Parasitology with over 125 major scientific publications to his credit.

**We would definitely like to have you as one of our satisfied advertisers.  
 Call for your media kit today... 520-541-1920**

**KOEHLER COMPANY, USA**

P.O. Box 11510 • Prescott, AZ 86304

1-800-320-6036 (orders only)

Fax: (520) 541-1906

**You can now buy Koehler on line.  
 Visit our new site at [www.koehlerusa.com](http://www.koehlerusa.com)**

**Mynax®  
 Peaca (Calc. EAP)®  
 Lombic®  
 Canax®  
 Trophicard®  
 Unizink®**